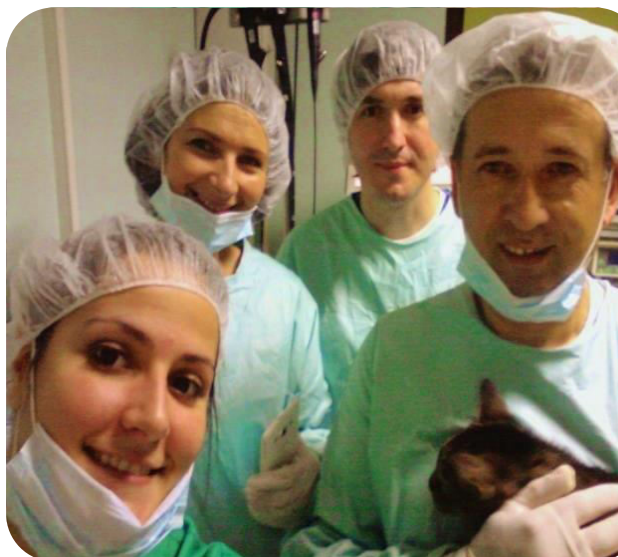

Laparoscopic surgery at 'IVAVET' clinic



Picture 1. Expert team at IVAVET clinic, Belgrade, Serbia. In front from right to left are Ivan Jevtić, DVM, and doctor specialist for laparoscopic surgery, owner and the main surgeon at IVAVET clinic. Next to him is Marija Pavlović, DVM, intern at IVAVET clinic. Behind from left to right are Biljana Jevtić, VT and owner at IVAVET clinic. Next to her is Radenko Savić, DVM, doctor specialist for intern medicine in small animals at IVAVET clinic.

Laparoscopic surgery is a minimally invasive surgery, a technique that allows the intervention to be performed by using multiple small abdominal incisions. Specialized camera with fiber-optical fibers (laparoscope) is introduced through one of these portals in order to allow visualization of the internal contents of the abdomen. Similarly, through other portals surgical instruments necessary for the intervention are inserted into the abdominal cavity.

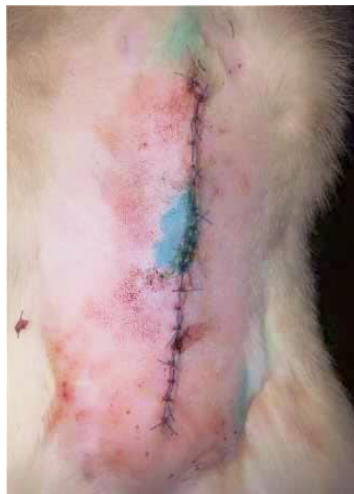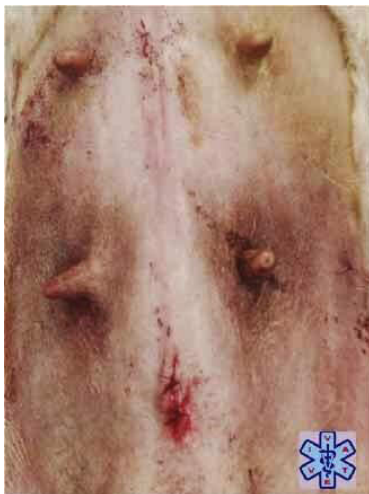Laparoscopic surgery at 'IVA VET' clinic is performed by the team of experts. 'IVA VET' surgical team (picture 1.) utilizes advanced technology for the prophylactic, diagnostic, and therapeutic surgical procedures.

The most common type of surgery performed using minimally invasive technique is ovariectomy. This procedure is performed to prevent unwanted offspring, and to reduce the risk of infections and cancers of the female reproductive tract. Compared with traditional open ovariohysterectomy, laparoscopic ovariectomy is technically less complicated and time-consuming. Further, in a study published in the 2005 Journal of the Veterinary Medical Association has been documented that laparoscopic surgery diminishes pain, reduces the risk of hemorrhage and speeds recovery times up to 65%. In table 1. are presented laparoscopic surgery advantages over traditional open surgery.

Table 1. *Laparoscopic surgery advantages over traditional open surgery*

Laparoscopic surgery	Traditional open surgery
Small incisions (less tissue trauma)	Longer incision (extensive trauma)
Quick recovery time-one day	Long recovery time-up to two weeks

Low risk of infection- in proportion with size of surgical wound	High risk of infection - in proportion with size of surgical wound
No formation of postsurgical hernia and adhesions	Possible formation of postsurgical hernia and adhesions
The intestines (bowel movements) are usually somewhat lazy, most commonly for a day	The intestines (bowel movements) are usually somewhat lazy for a few days
Significantly smaller scar tissue after surgery	Highly visible and characteristic scars
No need for Elizabethan collar or body	Mandatory use of E-collar or body
No tearing or need to remove surgical thread	Possible risk of tearing thread
Less stressful postsurgical recovery	More stressful postsurgical recovery
Reduced risk of bleeding during and after surgery	More frequent appearance of bleeding during and after surgery
Less use of painkillers	Required use of painkillers



Picture 2. On left is presented tissue appearance after laparoscopically performed surgery.

On right is presented tissue appearance after traditional open surgery.

The most common reasons for laparoscopic intervention are:

- Diseases causing acute or chronic pain in abdominal or pelvic cavity.
- Visualization of miscellaneous growths and patches in abdominal cavity, and collection of various samples (biopsy) for pathohistological examination.
- Ovariectomy and ovariectomy
- Determining possible causes for free fluid accumulation in abdomen.
- Cancer staging for specific tumors.
- Surgical removal of tumors or organ invaded by tumor.

Laparoscopic procedures in abdomen cavity:

- Ovariohysterectomy (in this procedure both, ovaries and uterus are removed)
- Ovariectomy (spay), only the ovaries are removed
- Sterilization of male dog
- Cancer and cystic kidney surgery
- Hernia Repair
- Ultrasound guided percutaneous sampling (biopsy) of abdominal organs
- Surgery of polycystic ovaries
- Gastropexy (Bloat/GDV Prevention)
- Removal of various tumor masses

Pre-operative assessment

Animal owners should expect the following procedures to be preformed during the preparation for the laparoscopic intervention:

1. General physical examination to determine animal health status.
2. Laboratory blood analysis (1.Blood chemistry panel—Used to evaluate organ function, electrolyte status, hormone levels, and more; 2.Complete blood count—Gives us information on hydration status, anemia, infection, clotting ability, and the ability of the immune system to respond to disease)
3. Laboratory urine analysis (Checks the condition of the urinary and genital tracts and screens for conditions such as diabetes, liver disease, and Cushing's disease)
4. Abdominal ultrasound (enabling a partial examination of the abdominal cavity- A non-invasive, real-time, moving picture of your pet's abdomen, chest and heart)

Contraindication for Laparoscopic surgery

Absolute contraindications

- Diaphragmatic hernia
- Septic peritonitis
- Conditions in which conventional surgical intervention is obviously indicated

Relative contraindications

- Obesity (obscure the view of many organs)
- Poor patient condition
- Ascites

- Poor clotting time
- Patient body weight <2 kg (instrument size)
- Patient that is a poor anesthetic risk or an extreme surgical risk

Patient preparation before surgery

Owners should withhold food for 6-12 hours (over night) before surgery.

Anesthesia for laparoscopic surgery

Laparoscopic surgery is routinely performed in general anesthesia.

Laparoscopic Surgery Procedures in general

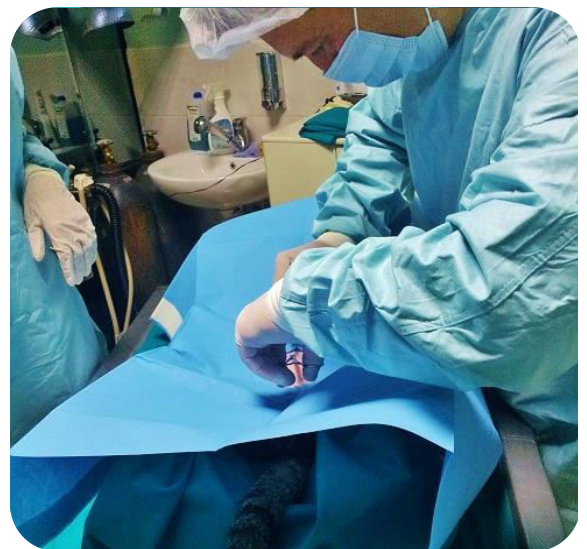
Preoperative preparation of patient

Empty urinary bladder for a better visualization of the abdominal cavity and to minimize the danger of tapping. Position the patient. Aseptically prepare the surgical field in the standard fashion.

Surgery

A surgeon makes one initial incision (picture 3.) commonly in the navel area. Then, a small needle is inserted through this incision, through which carbon dioxide gas can be pumped into the abdomen to inflate it allowing for better visualization of the abdomen's contents. Pressure in abdomen (picture 4.) must not be higher than 15 mm Hg (maintain the abdominal insufflation pressure at 12 to 15 mm Hg). If pressure in abdomen is higher, patient respiration will be impeded.

Next, a laparoscope is inserted through one of the incisions. The camera illuminates the interior of the abdomen and transmits high-quality, magnified images to a video screen in the operating room, allowing for precise maneuvering. After that, surgeon can begin with organ examination. If required, more incisions are made on abdomen to insert instruments (basic equipment and instruments required to perform laparoscopic surgery in dogs and cats are listed in table 2.), and perform the surgery or/and sample collections (biopsy). Once the procedure is completed, the carbon dioxide is let out of the abdomen and the incisions are closed using stitches or clips.



Picture 3. First incision in naval area

Table 2. Basic equipment and instruments

1.Endoscopic tower

monitor - camera system - light source - CO2-insufflator - recording system - suction device

2. Laparoscope

3.Laparoscopic staplers

4.Retractors

5. Blunt and port trocar

6. Veress Needle

7. Suture material

8.Bipolar forceps (for coagulation)

9.Grasping forceps

10. Scissor forceps

Postoperative procedures

- ✚ Any collected tissue or liquid sample during laparoscopic surgery will be sent for further pathohistological examination. Results of those analyses can be expected few days after the procedure.
- ✚ Postoperative recovery after the laparoscopic surgery is much faster, safer and less stressful for your animal companion.

Duration of laparoscopic surgery

Depending on the complexity of procedure, laparoscopic surgery can last anywhere from half an hour to several hours.



Picture 4. Few parts of required laparoscopic equipment.

Three portal laparoscopic cat sterilization performed by cutting both ductus deferens without testicle extraction: Case report

Case description:

A seven month old half-breed cat named Lion (picture 1.) was presented to our clinic “IVAVET” for the sterilization. The patient’s caring owner wanted to know which surgical procedure would provide safer, less stressful and easier recovery to her loving animal companion. In addition, she wanted to know if there is any possibility to perform sterilization without removing testicles, thus Lion’s aesthetic appearance could stay undisrupted. Therefore, we thoroughly presented to her all possible solutions and recommended laparoscopically performed sterilization achieved by cutting both vas deferens without need to remove gonads.

Aim of this minimally invasive surgery is cutting the tubes (ductus deferens) that transport sperm from the testicles to the penis, without removing gonadal glands. By cutting these tubes permanently sterile animal retain hormonal balance due to kept ability to produce testosterone. Moreover, after this procedure there will be no need for any kind of special diet.



Picture 1. Patient, seven month old cat named Lion

The patient’s owner accepted our advice so we obtained a signed permission form to perform laparoscopic sterilization, including permission to convert to an open procedure, should it be necessary.

Clinical finding

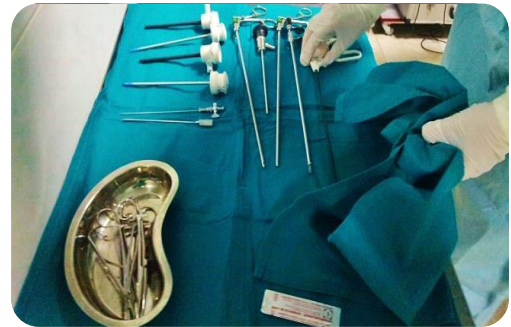General physical examination and laboratory analysis indicated Lion’s good health condition confirming him as ideal candidate for laparoscopic intervention. Examination revealed a slightly elevated body weight (3.9 kg).

Patient and instrument preparation for laparoscopic surgery

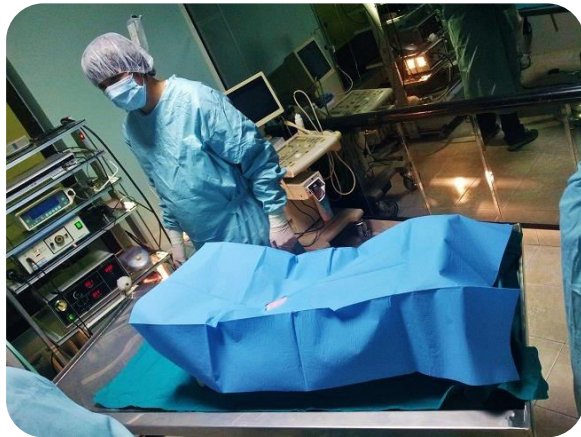Discarding our professional advice the owner fed her cat night before surgery. Consequently, cat vomited food, luckily for us before surgery took place. We prepared and sterilized all instruments (picture 2.), and put them on instrument table near operating.

Surgery

Anesthesia was achieved with appropriate dose of the domitor/ketamidor combination. We use this combination during surgery because it provides a suitable anesthesia for cats characterized by rapid induction, good muscle relaxation, good analgesia and bradycardia. During anesthesia our nonsterile assistant monitor all patient vital functions, instruments and keep connecting cables outside of patient sterile zone.



Picture 2. Basic sterilized instruments

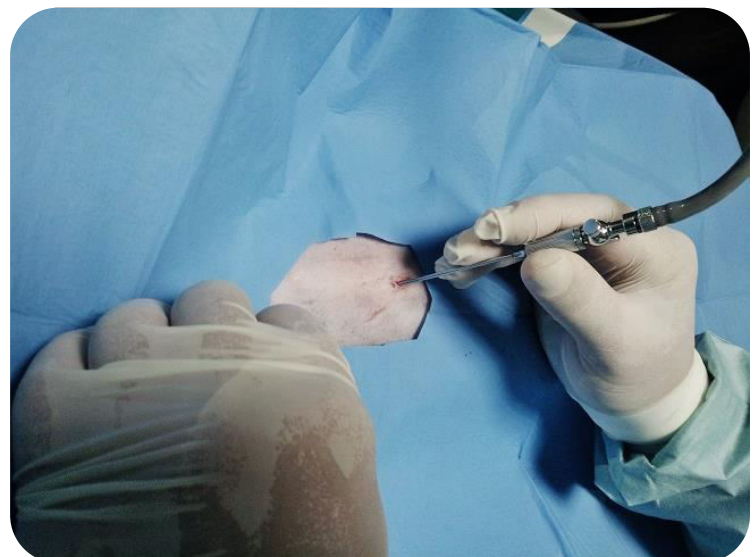


Picture 3. Cat position during procedure

Patient was restrained in dorsal recumbency on positioner that has been securely attached to the surgery table, and the surgical field was aseptically prepared in the standard manner for all abdominal operations (picture 3.). Next to the umbilicus we made a small skin incision (1 cm), through which we placed the Veress needle. While placing the Veress needle we were very vigilant in order to avoid damage to internal abdominal content (especially spleen or liver).

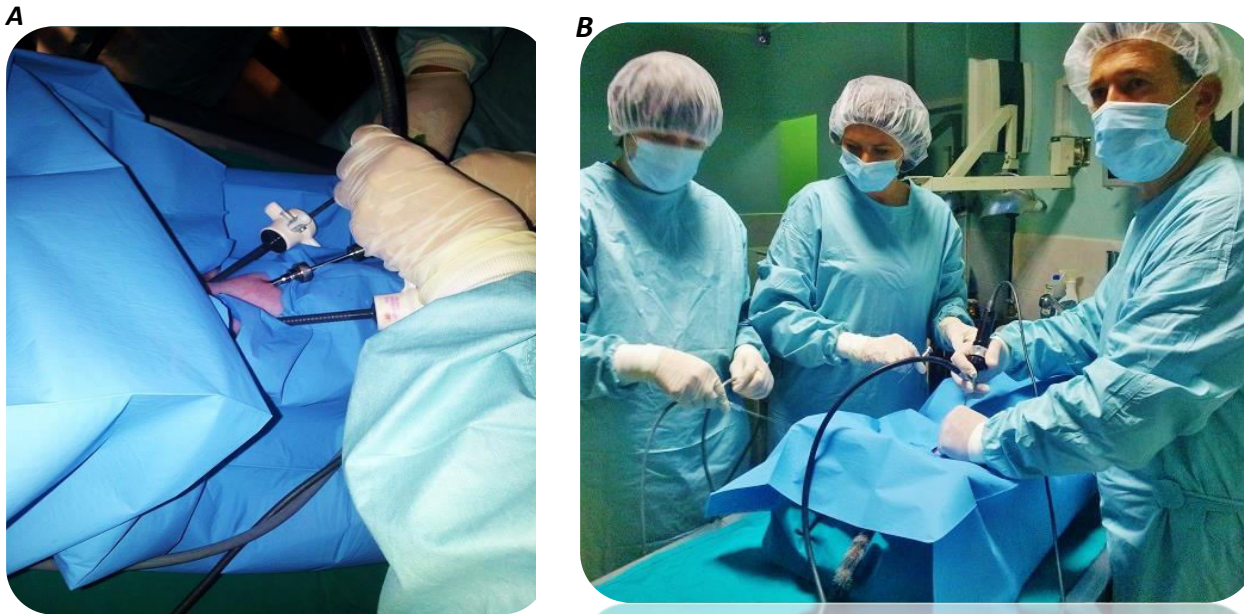
After penetrating the abdomen we attached the insufflation line to the Veress needle (picture 4.), turned the carbon dioxide gas on and started insufflation to establish pneumoperitoneum.

After that, we removed the Veress needle and in the same port we placed primary trocar through which we inserted laparoscope with a video camera and light source. After initial exploration with laparoscopic camera we placed two more lateral secondary ports (picture 5). Through this ports secondary trocars were placed, lateral to the primary trocar and halfway between the umbilicus and pubis. We used these two secondary ports to insert required instruments and to make easier access to the vas deferens.



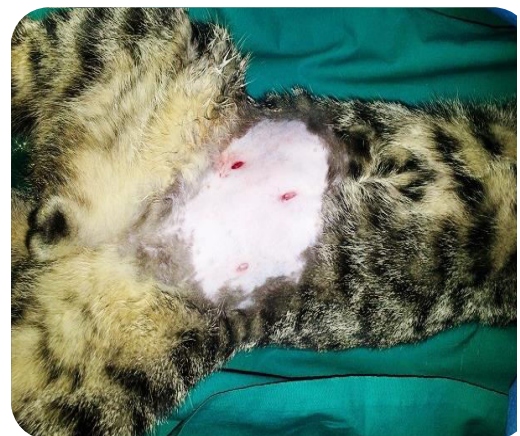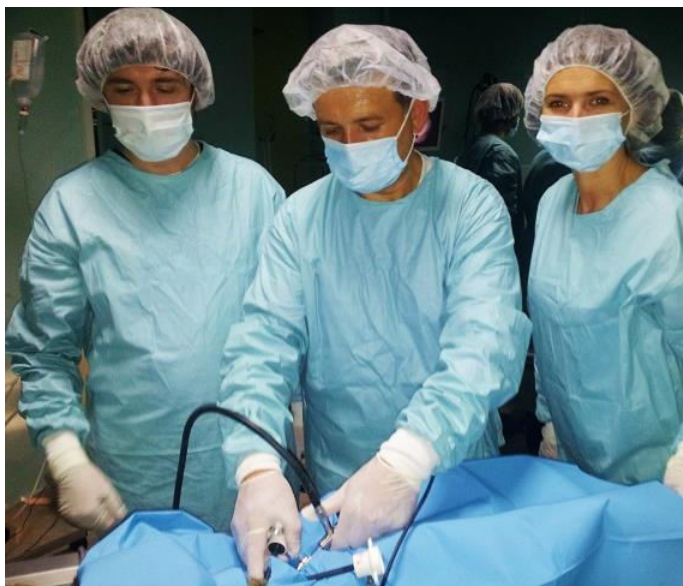Picture 4. The Veress needle

Laparoscopic procedure was observed on video monitor placed in the operating room so that all team members could supervise whole procedure.



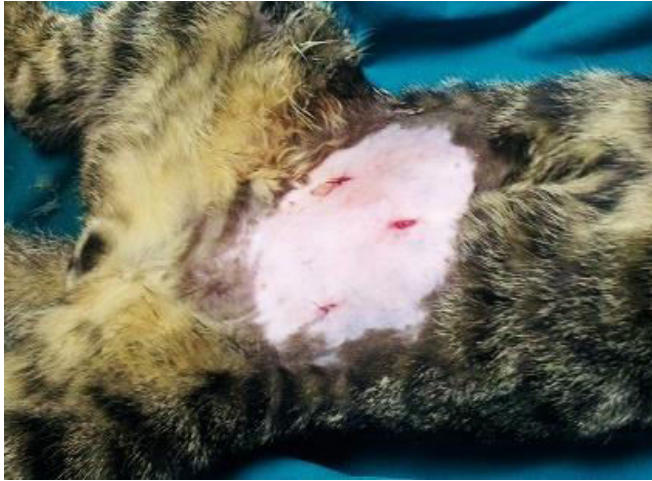Picture 5. A. You can see three trocars (one primary, two lateral secondary). B. Primary trocar trough which is inserted Laparoscope with video camera and light source.

First, in inguinal area we located left ductus deferens, using laparoscope. Second, with grasping forceps we elevated previously located left ductus deferens (as much as it was possible, look at picture 8.), inserted through one of the secondary ports. Third, through other secondary port we inserted bipolar forceps with an electro generator and coagulated one small place on the left ductus deferens. Finally, after removing bipolar forceps we used same port to insert scissor forceps and transect left ductus deferens. We have done the same process on the right ductus deferens.



Picture 6. On left you can see removing of instruments, after successful intervention. On right you can observe small portals left after removal of laparoscopic equipment.

We thoroughly checked for any bleeding or tissue damage before removing all instruments (picture 6.). After intrabdominal administration of antibiotics, deflating abdomen and removing trocars we sutured all ports using 3-0 thread for cats, in standard manner.



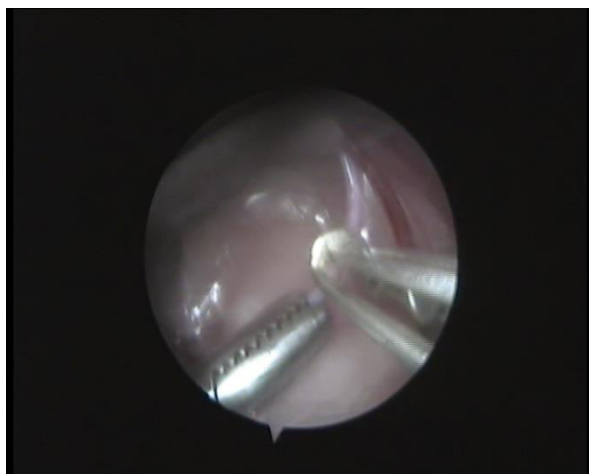***Picture 7. Secondary ports sutured.
Primary still not, but will be also
sutured.***

Postsurgical treatment

Lion was released home within a few hours after surgery. He didn't show any signs of pain or altered general condition. We prescribed a postoperative analgesic for three days and instructed owner to return in a week for recheck.

Conclusion

Laparoscopic vasectomy performed by cutting tubes is more challenging for a surgeon but for the patient is undeniable better due to faster recovery time, decreased stress and pain, improved visualization, undisrupted hormonal balance and last but not the least important unchanged aesthetic appearance of your animal companion.



Picture 8. Ductus deferens elevated with grasping forceps (instrument on the left) and coagulated with bipolar forceps (instrument on the right) on the same place where it will be transected.